

Preliminary Study to Verify the Transdermal Delivery of a Micronized Gel with Active Ingredients Using DermaWave“No Needle Mesotherapy” (NNM)

GUSTAVO LEIBASCHOFF M.D.*, A. JULIANA MELAMED LEIBASCHOFF M.D.***
ALBERTO HUGO CROCI M.D.****, SALVADOR NIETO M.D.**

ABOUT THE AUTHORS

*PRESIDENT,
INTERNATIONAL
UNION OF LIPOPLASTY

**PRESIDENT,
INTERNATIONAL
CONSULTANTS OF
AESTHETIC MEDICINE

**DIRECTOR ARGENTINE
FOUNDATION FOR
RESEARCH IN LYMPHATIC
PATHOLOGY

***CHAIRMAN,
INTERNATIONAL SCHOOL
OF MESOTHERAPY

****SPECIALIST IN
NUCLEAR MEDICINE,
BUENOS AIRES,
ARGENTINA

SUMMARY

An instrumental study using radioisotope lymphography was carried out to determine the effectiveness of the DermaWave No-Needle Mesotherapy device. The DermaWave device utilizes techniques of molecule delivery called threshold electroporation and ‘Aquaphoresis’ facilitating transdermal delivery of different topical active ingredients. The active ingredients are encapsulated in a standardized, micronized gel specifically designed to be used with the device. The study objective was to monitor absorption of the gel ingredients to a specific depth in tissue and to determine if the active ingredients were present after absorption in the lymphatic system of patients with Edematous Fibrosclerotic Panniculopathy (Cellulite).

The study had a prospective, longitudinal, and double blind design. Ten (10) female patients were selected for inclusion in the study all with similar grades of cellulite. The patients were divided into two groups -- the first group received a regular ultrasound gel that did not contain active ingredients. The second group received the specially formulated micronized gel containing the active ingredients.

Radioisotope Lymphography was used as the main non-invasive instrumental method to detect the presence of the gel ingredients at specific time intervals after delivery. Radioisotope lymphography of the first group showed no absorption of the active ingredients in the presence of the ^{99m}Tc . Radioisotope lymphography of the second group showed the presence of the radioactive substance (^{99m}Tc Tecnecio meta stable).

CONCLUSION

The study confirmed that the micronized gel containing the active ingredients was absorbed and was present in tissue at specific time intervals up to 24 hours after administration.

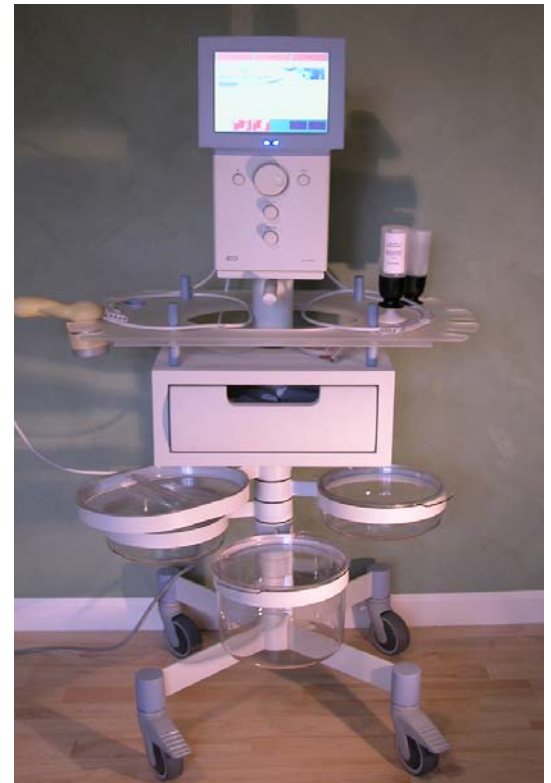KEY WORDS

- EDEMATOUS FIBROSCLEROTIC PANNICULOPATHY
- CELLULITE
- NONNEEDLE MESOTHERAPY
- RADIOISOTOPE LYMPHOGRAPHY

INTRODUCTION

The occurrence of cellulite is a widespread problem for females of all age groups. Estimates suggest that 80-90% of all females will suffer from the condition at some time during their lifespan. Depending on the severity of the condition (grades 1-5) cellulite manifests itself as a significant perceived cosmetic defect for most women. Higher grades of cellulite are often accompanied by tissue tenderness and pain as well as physiological problems related to the unattractive appearance of the body area affected. The duty of physicians working in the medical aesthetic environment is to provide the most effective and appropriate scientific treatment methods to repair tissue damage and pathological disorders, as well as being effective in achieving the best possible aesthetic results.

Edematous fibrosclerotic panniculopathy (EFP) is considered an endocrine based metabolic pathology that includes interstitial matrix alterations. Important changes also occur at the level of the microcirculation -- microaneurysms, microthromboses, slow down of red blood cells and altered capillary permeability together with lipedema particularly at the initial stages of the pathological process.



**DERMAWAVE NO-NEEDLE
MESOTHERAPY SYSTEM**

Microcirculatory alterations cause a slow down in the circulatory process that favors lipogenesis. Lipedema also affects fibroblast metabolism leading to perivascular glycosaminoglycans (GAG) loss. This, in turn, decreases blood flow, resulting in further microcirculatory slow down and more lipogenesis that compresses the inter-adipocyte capillaries. The vicious circle is on-going and continuous when no adequate treatment plan is applied.

These events were described by Binazzi and Curri (1978) who histologically demonstrated microvascular alterations during the three stages of the disease -- edema, fibrosis, and sclerosis. The name EFP derives from these chronological evolutionary phases.

In short, cellulitis or EFP is an endocrine – metabolic, micro-circulatory alteration accompanied by subcutaneous cellular tissue hypertrophy. The condition triggers a vicious cycle -- as microcirculation lessens, greater lipogenesis is detected, and conversely, as blood flow improves, greater lipolysis is observed.

Cellulite is defined as a ‘skin irregularity’ which visually appears in the form of a ‘mattress’ of dimpled skin and may be associated with various types of dermal and hypodermal tissue alterations, i.e. alterations of adipose tissue, connective tissue, the venous lymphatic system and the interstitial matrix. The interstitial matrix and the connective tissue, as well as the microcirculatory system, form a ‘physiological hub’ where various fundamental trophic substances, essential for cell life, circulate freely as long as the ‘hub’ functions correctly.

Treatments are aimed at increasing microcirculation with subsequent improvements in interstitial matrix basal regulation, fibroblast function increases, interstitial edema decreases, and increases in lipolysis to improve the EFP condition.

DERMAWAVE NO-NEEDLE MESOTHERAPY

In the two years, different devices have been promoted by manufacturers that claim to introduce medicine through the skin without needles. These devices appear attractive to aesthetic practitioners, especially those who are already performing or considering conventional injection mesotherapy. Obviously, downsides for patients undergoing injection mesotherapy are pain, erythema, potential for allergic reaction and the bruising associated with any multiple injection strategy. For the physician, injection techniques require personal involvement and a well practiced technique, so the potential for delegation is limited.

Unfortunately, most of the devices that are on the market are not supported by quality research that proves their clinical effectiveness.

The authors of this study believe that one of the principle goals of

aesthetic medicine is to provide treatments with a strong scientific research background to support the effectiveness and safety of those techniques in a diverse patient population.

The Dermawave No Needle Mesotherapy System is a Class II device using a dual wavelength laser, and three complex electrical waveforms, delivered in sequence, to produce an effect called threshold electroporation and Aquaphoresis. The two methodologies are delivered via a hand-held applicator and a series of pre-programmed protocols to facilitate transdermal delivery of permeation enhanced topical ingredients. These ingredients are formulated into a standardized 'cocktail' containing some of the same ingredients used in injection mesotherapy.

The active ingredients, are compounded in the form of micromolecules, in a proprietary, permeation enhanced gel designed to be used with the device.

KEY STUDY HYPOTHESIS

To determine if the gel containing the active ingredients is delivered to the required site of action and is present in the lymphatic system at various time intervals after treatment.

The study utilized sophisticated radioisotope lymphography to reveal the presence in the lymphatic system of a radioactive substance used with the micronized gel. Presence of the radioactive material in the lymphatic system validates the study hypothesis

MATERIALS AND METHODS

The research was performed in Buenos Aires, Argentina with the scientific support and direction of Dr. Alberto Croci of the Salvador Nieto Foundation -- an organization dedicated to the study, research and treatment of lymphatic pathologies.

The study had a prospective, longitudinal, and double blind design. To maintain the double-blind condition, no one involved in the lymphography procedure was aware of which patient was treated with one gel or another.

GEL CHARACTERISTICS

The micronized gel containing the medication was prepared (College Pharmacy, Colorado Springs, USA) for use with the DermaWave NNM device to include the following medications:

- 1, 3, 7-Trimethylxanthine
- Adenosine
- Algesium

- Aminophylline
- Amino Acid Complex
- Antioxidant Complex
- Artichoke Extract
- Arginine
- Ascorbyl Palmitate
- B-1, 3-Glucan
- Beta Glucan
- Biotin
- Caffeine
- Camu Camu (Myrciaria Dubia)
- Canelle
- Carbamide (Urea)
- Carnitine
- Centella Asiatica
- Grapefruit Seed Extract
- Grape Seed Extract
- Green Tea Extract
- Lysine
- Manganese SulphateMannitol
- Methionine
- MSM (Methylsulfonylmethane)
- Naringin Extract
- Phosphatidylcholine
- Procaine
- Rutin

Serine
 Silica
 Sodium Salicylate
 Trace Minerals
 Valine
 Xylitol
 Yohimbine
 Zinc Sulphate

The other gel used in the study was a standard ultrasound gel with similar viscosity characteristics as the active ingredient gel.

Each of the gels was marked with 10 mCi of 99 mTc (tecnecio meta stable), in a mixing technique designed to homogenize the samples.



DRY ACTIVE INGREDIENTS ARE ADDED TO THE PERMEATION ENHANCED GEL TO ENSURE STABILITY AND ADHERENCE TO A STANDARDIZED FORMULA.

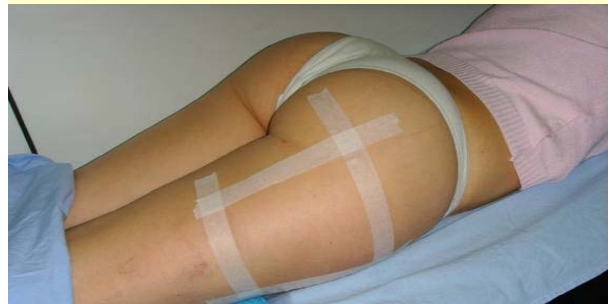PATIENT SAMPLE

A total of 10 female patients aged 32 to 45 years were selected. All patients presented with the same pathology -- mild lipodystrophy of the lateral area of the thigh without skin retraction, lipoedema, lymphoedema or phleboedema.

EXCLUSION CRITERIA

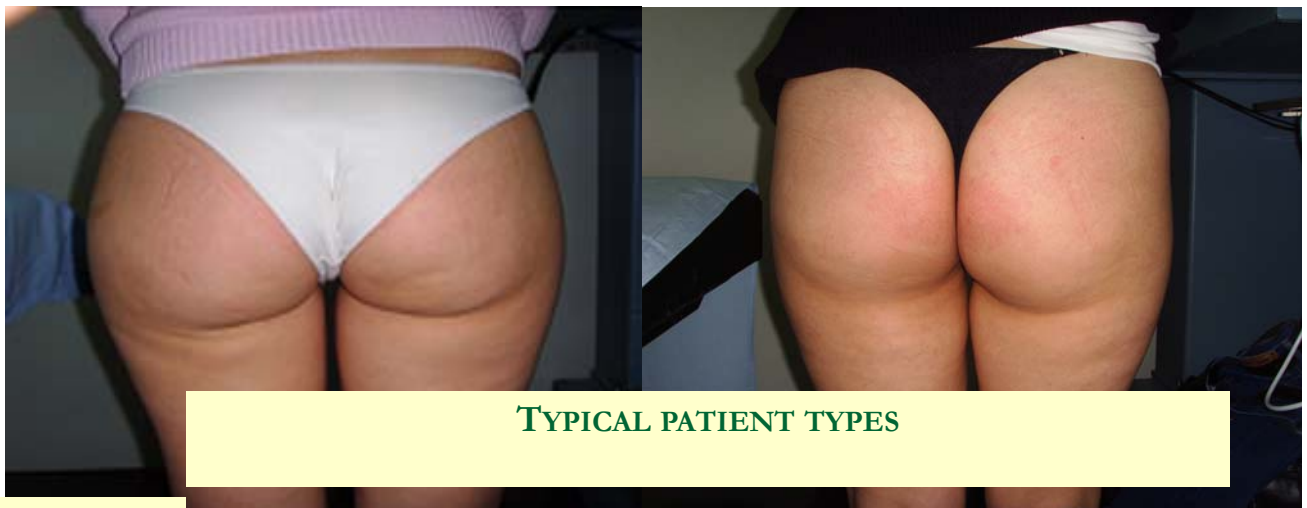
- Treatment for cellulite within the past 1 month of the study period
- History of deep vein thrombosis within the past 2 years
- History of congestive heart failure
- Occlusive arterial disease of the legs
- Pregnant or lactating women
- History of topical medication usage within 2 weeks of the study period
- BMI exceeding 30,
- Saphenous and collateral varicose veins
- Phlebolympoedema,
- Systemic lymphoedema (positive Stemmer's test),

- Venous insufficiency (instrumental and clinical diagnosis)
- Post-liposculpture
- Other anti-cellulite treatments in progress,
- Menopause and Pre-menopause,
- Patients with evident pathologies in progress



**ANTERIOR/SUPERIOR AREA OF
RIGHT THIGH**

The area selected to carry out the No-Needle Mesotherapy treatment using either of the gels, was the anterior superior area of the right thigh (saddle bag area). The surface was marked and the anterior superior hip bone was noted as a reference point.



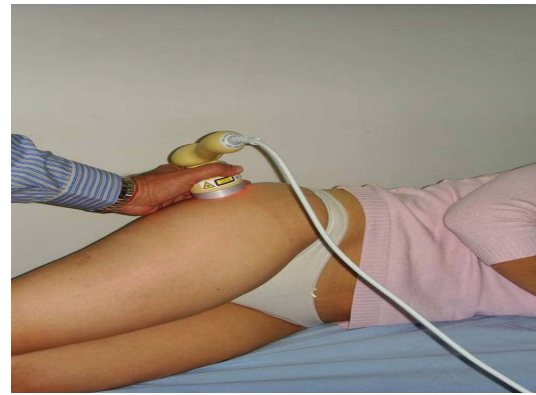
TYPICAL PATIENT TYPES

Patients were divided into two groups:

Group One - Comprises 5 patients that received a standard ultrasound gel with no active ingredients and marked with Te99 in the study area.

Group Two - Comprises 5 patients that received the micronized gel carrying the active ingredients marked with Te99 in the study area.

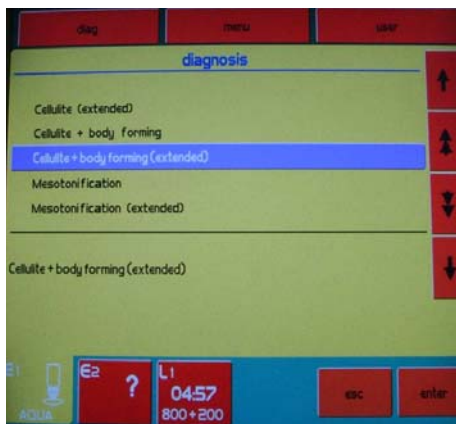
Delivery of both gels utilized the DermaWave NNM device. The optimum program adequate for the pathology was selected to be 'cellulite extended' consisting of a 5 minutes laser application followed by 21 minutes of three electrical waveforms. A uniform voltage of 50 V was selected consistent with patient comfort.



APPLICATION OF LASER

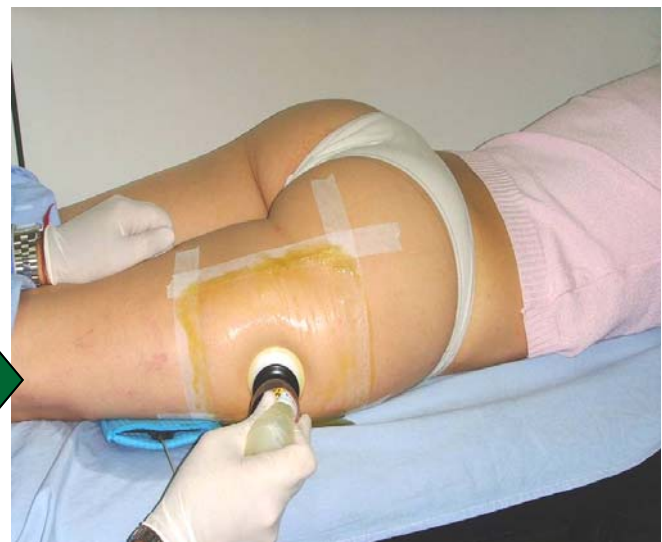

GEL APPLICATOR WITH SUPPLY OF TE99



PROGRAM SELECTION

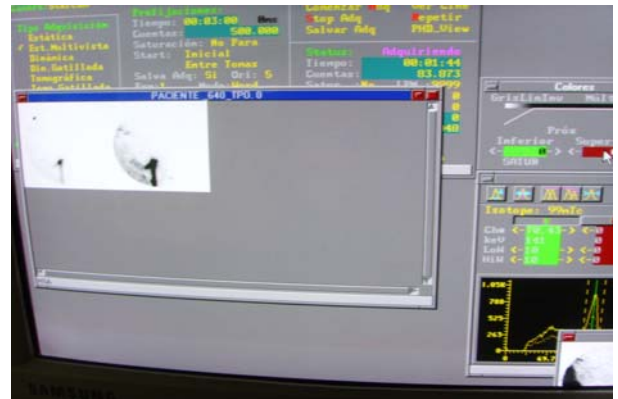
APPLICATION OF GEL USING DERMAWAVE APPLICATOR. GEL IS DELIVERED ONTO TISSUE BY GENTLY SQUEEZING DISPENSER BOTTLE, FORCING GEL THROUGH ELECTRICAL FIELD AND ONTO SKIN.



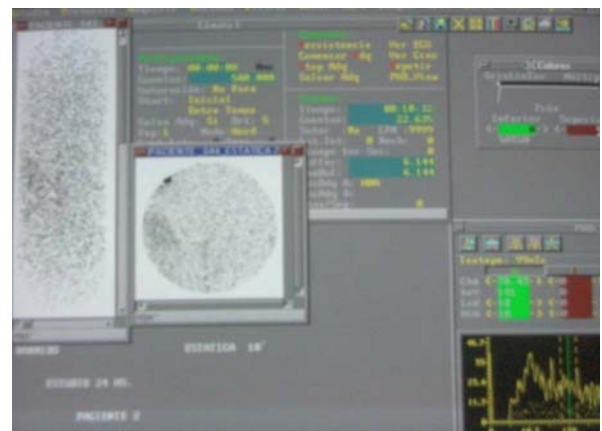In all cases, the application was done on the saddle bag area of the upper right thigh, over a predetermined and perfectly demarcated surface. After delivery of the gels, radioisotope lymphography was used as a non-invasive, instrumental method of tracking the gel through tissue. The test was performed according to standard methods. The radioactive substance used was ^{99m}Tc Tecnecio Meta stable -- selected due to the short average life of the material at 6.4 hours at a level of 140Kev. This mix produces substantially less risk of contamination to patients and operator.

The images of the bilateral inguinal region and pelvic area under treatment were recorded using a Gamma Planar device with collimator, immediately post treatment and 2-4 and 24 hours after treatment.

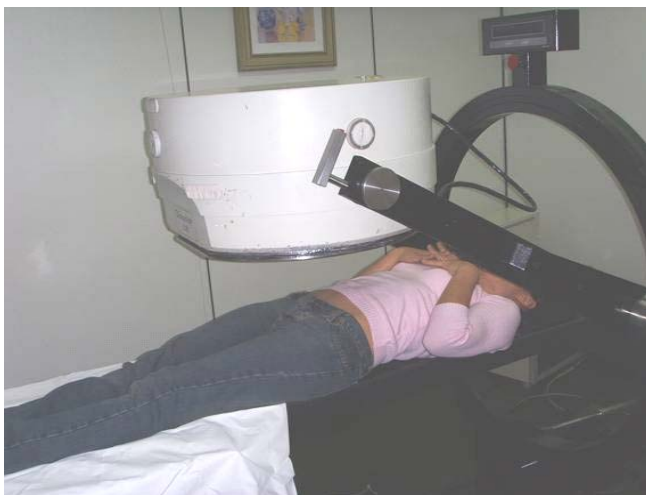After 24 hours a sweeping anterior thorax abdominal pelvic scan was added. In all the cases the anterior superior hip bone was used as a reference.



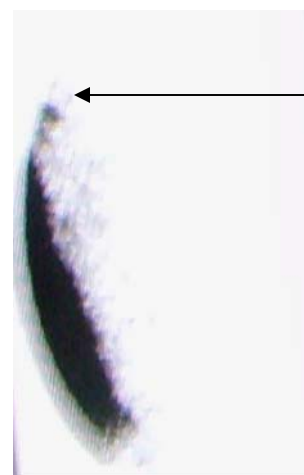
BILATERAL, INGUINAL AND PELVIC AREA IMAGES WERE TAKEN



AFTER 24 HOURS, A SWEEPING ANTERIOR THORAX-ABDOMINAL PELVIC SCAN IS PERFORMED



GAMMA PLANAR DEVICE POSITIONED OVER PATIENT

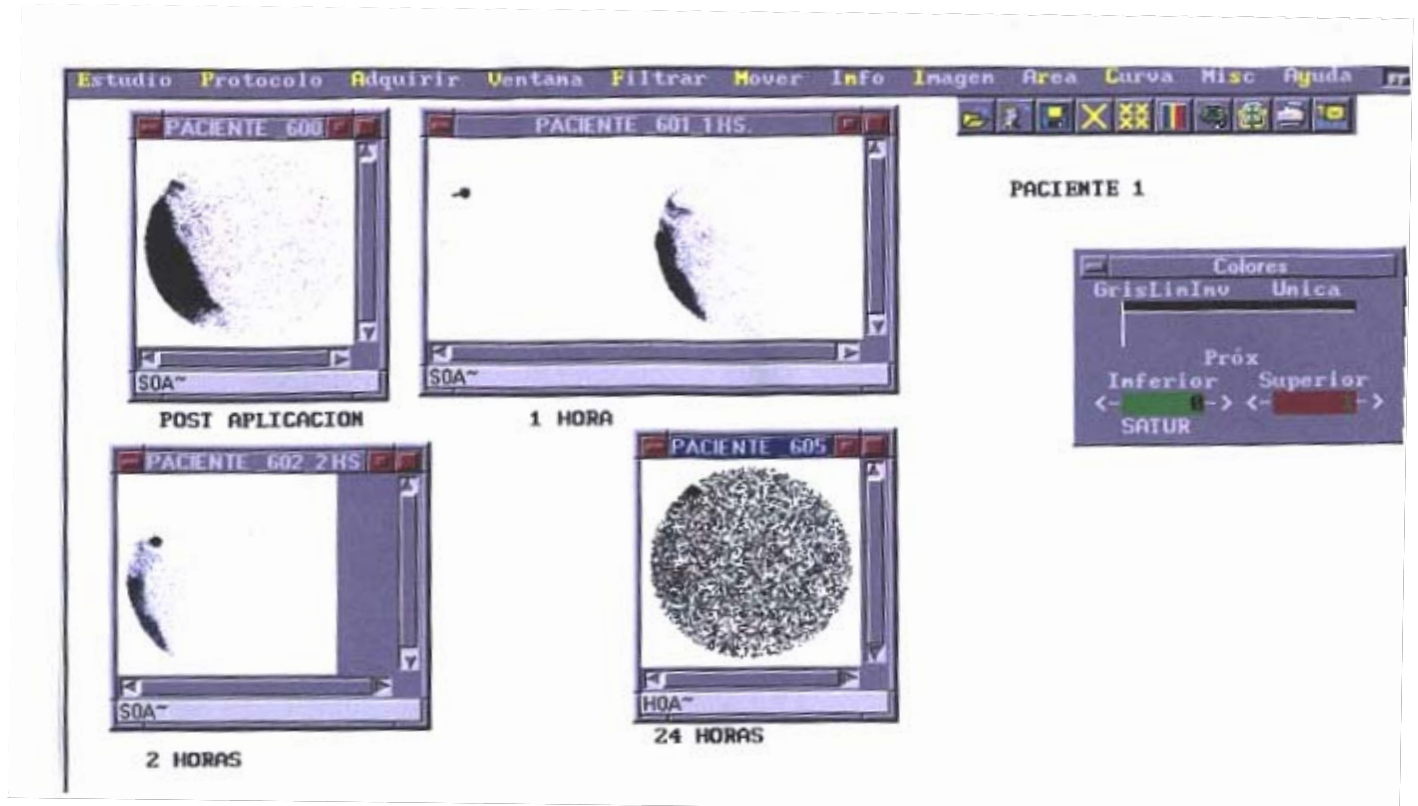


HIP BONE

THE ANTERIOR/SUPERIOR HIP BONE WAS USED AS A REFERENCE POINT

RESULTS & CONCLUSION

100 % of the lymphography scans of the first group showed no trace of the radioactive substance ^{99m}Tc .



GROUP ONE

SCANS PERFORMED IMMEDIATELY POST APPLICATION OF THE GEL, A HIGH CONCENTRATION OF MATERIAL IS SEEN ON THE TREATED AREA. AT 24 HOURS SOME CONCENTRATION MAY BE SEEN ALBEIT AT SIGNIFICANTLY LOWER LEVELS. NO LYMPHATIC STRUCTURES ARE VISUALIZED

LYMPHOGRAPHY SCANS OF GROUP TWO (WITH ACTIVE INGREDIENTS), DEMONSTRATES PRESENCE IN THE LYMPHATIC SYSTEM OF RADIOACTIVE ^{99m}Tc MATERIAL IN 100% OF PATIENTS. SCANS PERFORMED IMMEDIATELY POST APPLICATION OF THE GEL, SHOW A HIGH CONCENTRATION OF MATERIAL IS SEEN IN THE TREATED AREA. AT 24 HOURS SIMILAR LEVELS OF CONCENTRATION MAY BE SEEN. THERE IS A MIGRATION TO A STRUCTURE THAT CORRESPONDS TO A LYMPHATIC VESSEL


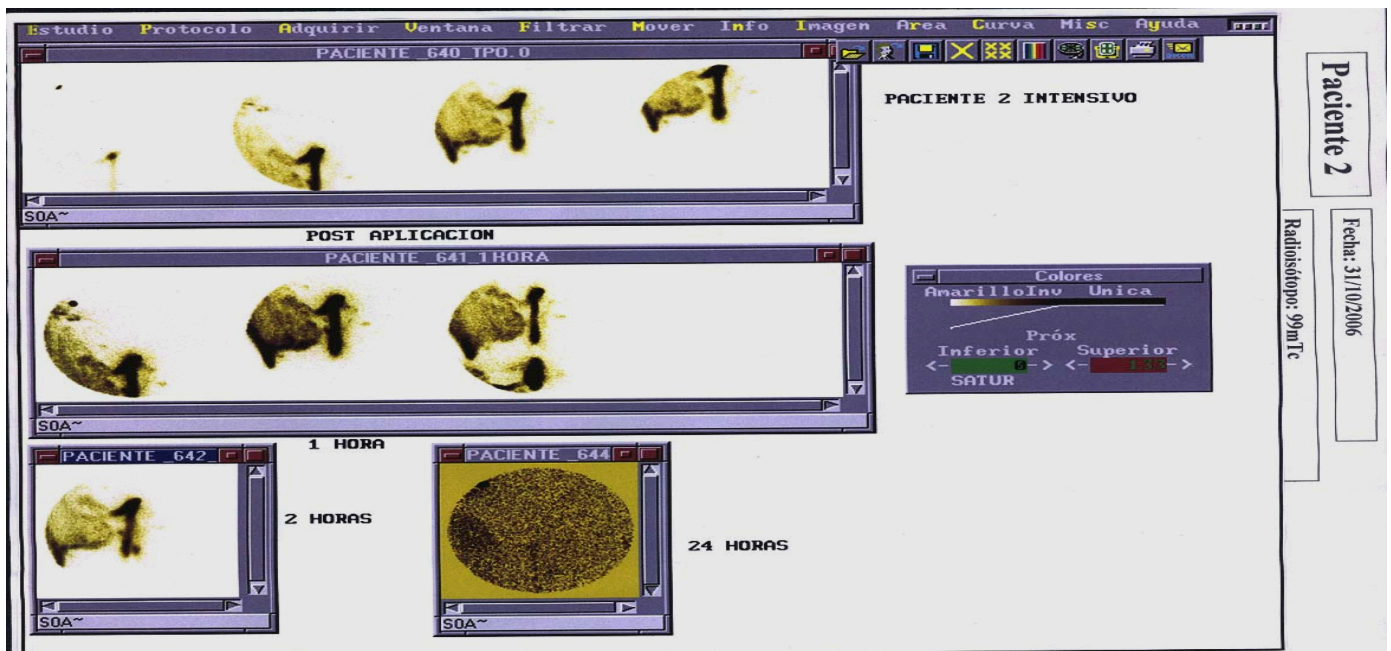

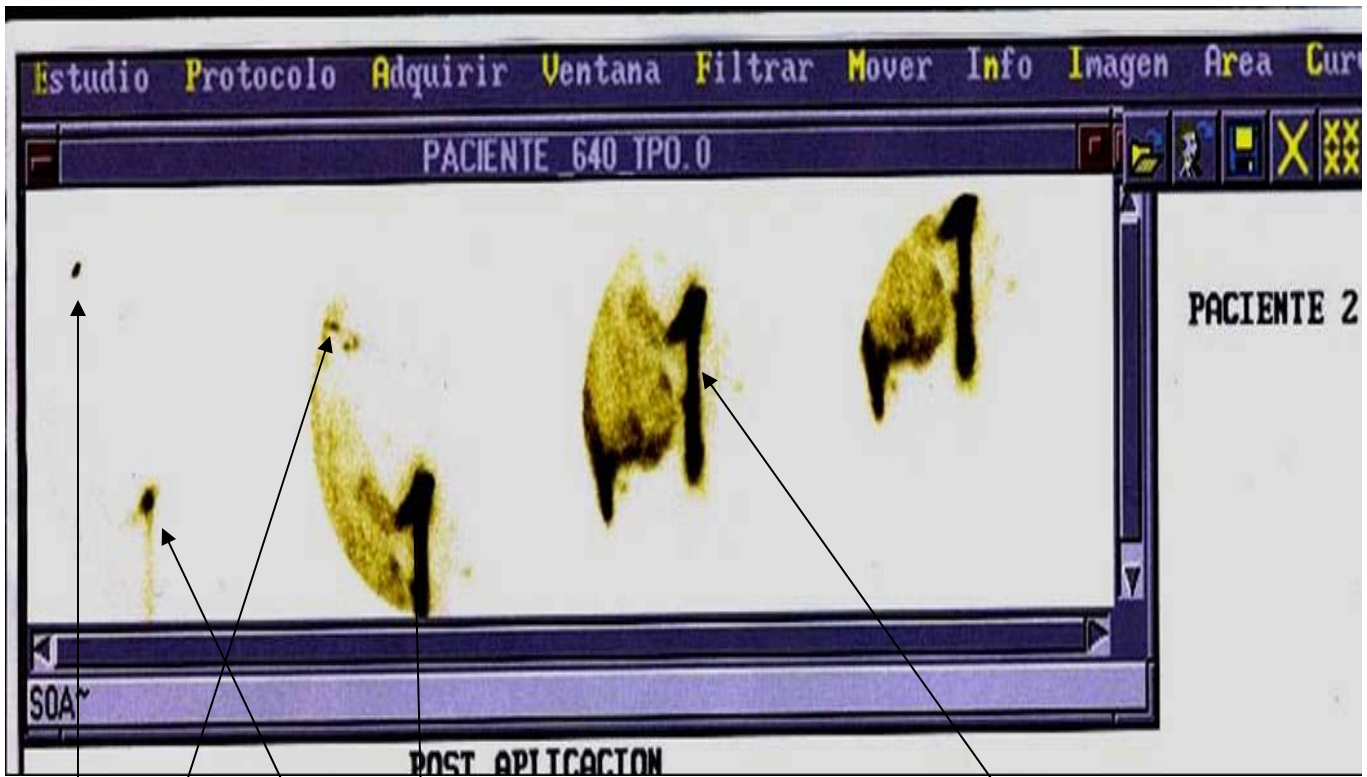


IMAGE FROM GROUP ONE SHOWING LACK OF MARKING IN THE LYMPHATIC SYSTEM





**ANTERIOR/
SUPERIOR
HIP BONE**

**LYMPHATIC
NODE**

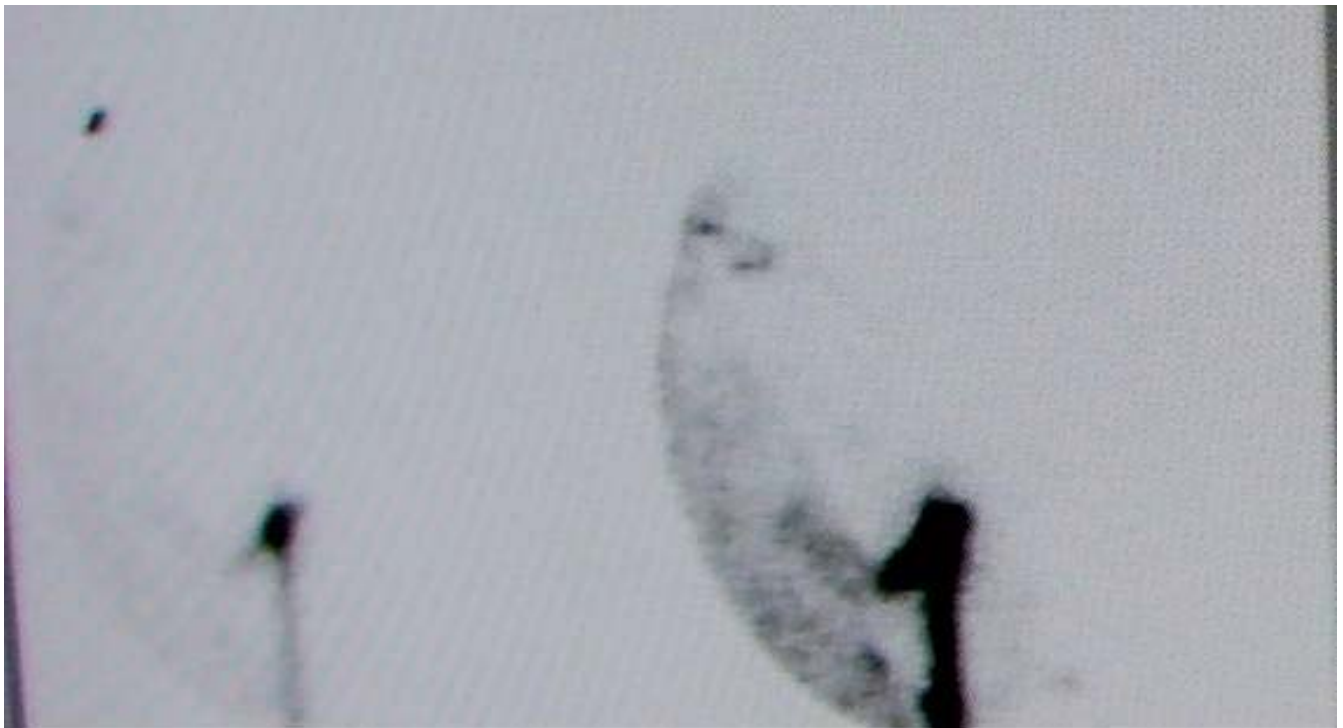**LYMPHATIC
SYSTEM**

IMAGE FROM GROUP TWO




GROUP ONE

THE ULTRASOUND GEL WITHOUT ACTIVES AND WITH Te99 MATERIAL IS CONFINED TO THE SKIN SURFACE WITH NO PENETRATION



GROUP TWO

THE ACTIVE GEL WITH Te99 IS SHOWN IN THE LYMPHATIC SYSTEM



Radioisotope lymphography reveals the presence of the marked micronized gel in the inguinal lymphatic system after the NNM procedure is performed and corresponding to the area that received the medication. The presence of actives in the lymphatics confirms that transdermal diffusion has occurred. Most important, the connective tissue comprising the extra cellular matrix and lymphatic pre-collector vessels has absorbed the medication. Using the DermaWave NNM System we believe that specialized formulations using permeation enhanced technology and micronized encapsulation techniques can penetrate to the extracellular matrix to modify the changes produced as a result of PFE (Cellulite).

This was a preliminary study and additional research is planned to determine if additional protocols used in the DermaWave System are also effective to produce transdermal diffusion of active gel medication.

It would be of great interest to evaluate the effectiveness of the drugs included in the gel and used for the treatment of different type of Cellulite . New studies could determine if a given medication increases microcirculatory flow and create lymphakinetic action.

References

- Allegra C., Pollari G., Antonini V., Curri SB., Pannicolopatia edematofibrosclerotica, *Minerva Mesoterapica* 1986 :1.
- Bacci P.A. - Il lipolinfedema: riflessioni e osservazioni cliniche , *Flebologia Oggi*, Torino Minerva Medica, N.2, pag.10. 21.1997
- Bjorntorp P., Sjostrom L. Number and sizes of adipose fat cells in relation to metabolism in human obesity, *Rev. Metabolism*, 1972.
- Ceccarelli M.: Cellulite: approccio diagnostico e terapeutico. *Atti 1 Congr Multid Chir Plast e Invecch* 9/12 Nov 1989
- Merlen JF, Curri SB, Sarteel AM, La cellulite, une mesenchimopatie discutée, *Sci. Med. Lille*, 1978
- Binazzi M., Papini M., Aspetti clinico istomorfologici in "La cellulite" di Rituffo - Bartoletti, *Salus Ed. Roma* 1983, 7-15.
- Merlen J.F., La part de la cellulite dans la douleurs vasculaires, *Angiologie* 18 ; 3 ; 21-24, 1966.
- Curri SB, Liposclerosi e microcircolo, *La dermoestetica*, 1, 6-7, 1990.
- Bilancini S., Lucchi M., Approccio al lipoedema, in *Linfologia*, n.1, 24-26, 1989.
- Bilancini S., Lucchi M., Tucci S., El lipedema: criterios clinicos y diagnosticos, in *Angiologia*, 4; 1990, 133-137.
- Campisi C.: Il linfedema, *Flebologia Oggi*, Minerva Medica Ed., 1997.1:23-29
- Curri SB, Linfedema, lipoedema, liposclerosi : una questione nosologica, *La medicina estetica*, Roma, 8.10.1984.
- Ceccarelli M., L'eccesso adiposo generalizzato e localizzato in medicina estetica, *Le Muse Editore. Roma* 1995.
- Albergati F., Menegon L., Turatello, Bacci P.A., Valutazione degli effetti microcircolatori dopo terapia della matrice extracellulare in pazienti con flebolinfedema, *Linfologia, Auxilia speciale, Bologna*, 8-11, 2001.
- Curri SB., Inquadramento nosologico e classificazione delle panniculopatie da stasi, *Flebologia* 1:15-19, 1990.
- Elsner, Merk, Maibach Eds: *Controlled Efficacy Studies and Regulation*; Springer 1999
- Godart S., Circulation lymphatique de la peau, *Rev. Med. Paris*, 9.549-556, 1969.
- Bacci P.A., Izzo M., Botta G., Mancini S.. Valutazione dell'azione antiossidante di un prodotto fitofarmacologico nelle sindromi cellulitiche, *Podologia*, Napoli 2002
- Curri S.B., *Microcircolazione*, Inverni della Beffa, Roma, 1982.
- Granger H.J., Role of the interstitial matrix and lymphatic pump in regulation of transcapillary fluid balance. *Microvs. Res.*, 18.2,209-216.1979.
- Granger H.J., Role of the interstitial matrix and lymphatic pump in regulation of transcapillary fluid balance. *Microvs. Res.*, 18.2,209-216.1979. Granger H.J., Role of the interstitial matrix and lymphatic pump in regulation of transcapillary fluid balance. *Microvs. Res.*, 18.2,209-216.1979

Casley Smith J., Fine structure properties and permeabilities of the lymphatic endothelium., *New Trends in basic lymphology – Exper. Suppl.* 14, Bale Birkhauser edit.p.19-40, 1981.

Piller N.B., Lymphedema macrophages and benzopyrones, *Lymphology*, 13.109-119.1980.

Bacci P.A. Il cosiddetto Lipolinfedema, *Flebologia Oggi*, Torino - Atti Congresso Nazionale Collegio Italiano Flebologia. Vol.2 N.1: 27-32 .-1998.

Foldi M., les maladies de lymphostasis et leur traitement, *Sem. Hosp.*, Paris, 51.9,488-486, 1975.

Bolton T., Casley Smith J., The in vitro demonstration of proteolysis by macrophages and its increase with Melilotus and Coumarine, *Experientia* 31.271-273, 1975

Martignani A, Scondotto G, Terapia farmacologica del linfedema con estratto naturale del meliloto, *Gazzetta medica italiana*,156 (2): 85-58, 1997

Vassallo C. Berardesca E, "Efficacy of a Multifunctional plant Complex in the treatment of a localised fat-lobular Hypertrophy", *American Journal of Cosmetic Surgery*, 203-208, Vol.18, N. 4.2001.

Leibaschoff GH, Coll, L & Desimone JG, "Non-invasive assessment of the effectiveness of Cellasene in patients with oedematous fibrosclerotic panniculopathy (cellulitis): a double-blind prospective study", *International Journal of Cosmetic Surgery and Aesthetic Dermatology*, 265-273, vol3, N4, 2001.

Leisbasshoff G., Cellulite, treatment and clinical approach, *American Journal of cosmetic Surgery*, 1997

Bacci P.A., Leisbasshoff G.,, *Las cellulitis, el protocolo BIMED*, Medical Books, Buenos Aires, 2002.

Merlen J.F., Microcirculation et Lymphatiques, *Symposium de Lymphologie*, Crans /Sierre, 1981.

S.E.Cross and M.S.Roberts University of Queensland, Princess Alexandra Hospital, Brisbane
Physical enhancement of transdermal drug application: Is delivery technology keeping up with pharmaceutical development 2004

Weaver Group Theory of Electroporation. MIT, *Biomembrane Electrochemistry* 235:447-470 1994
Theory of electroporation of planar bilayer membranes: predictions of the aqueous area, change in capacitance and pore-pore separation. FreemanSA, Wang MA 1994
Tissue electroporation for localized drug delivery. Weaver JC, Langer R 1995
Breaching the skin's barrier to drugs, Brian W.Barry
School of Pharmacy
University of Bradford UK
Nature Biotechnology 2004
The art of water transport in Aquaporins National Science Foundation and Science Magazine, www.ks.uiuc.edu/research
2006

